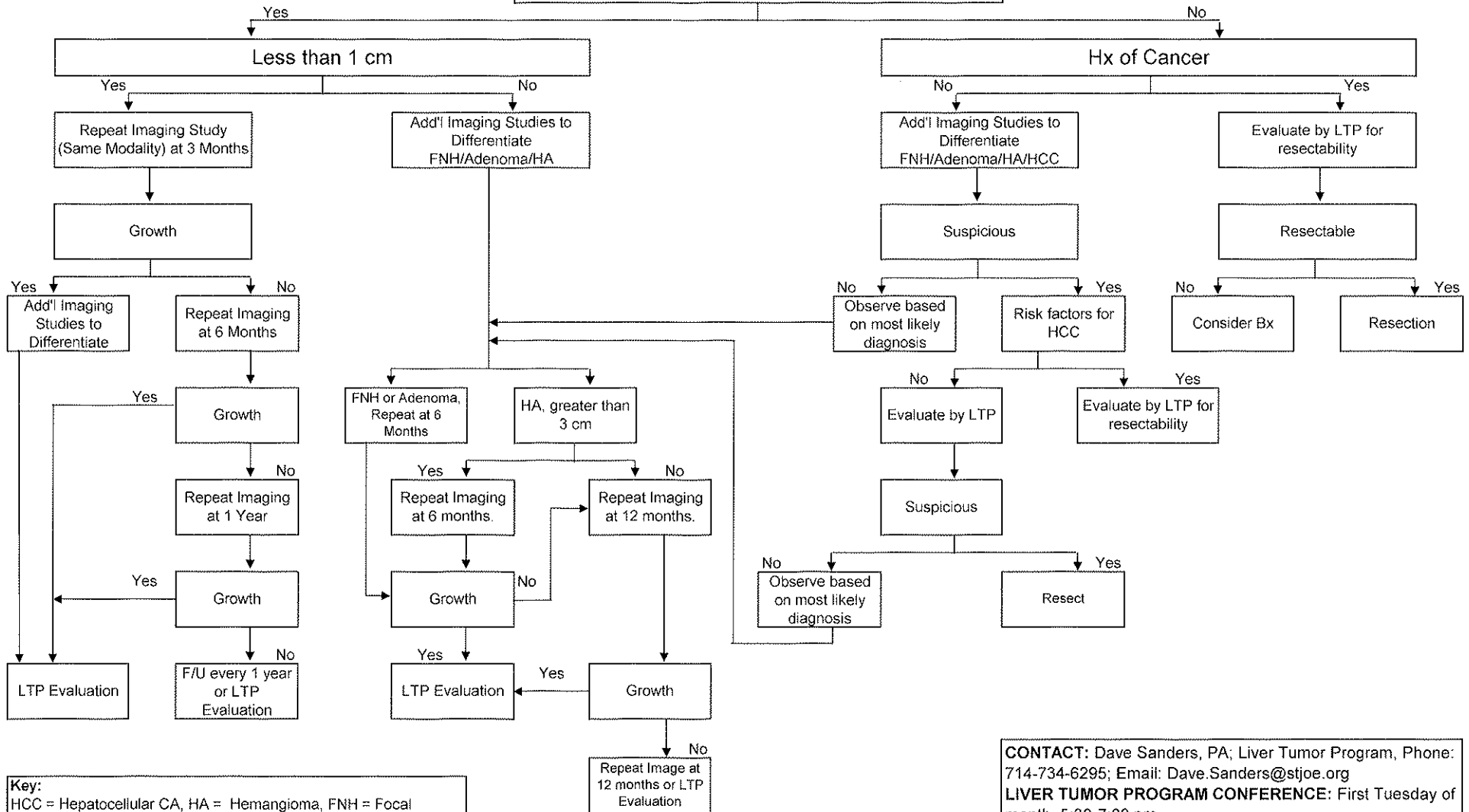


Single Hepatic Lesion, Radiologic Finding

Imaging Suggests a Benign Lesion



Key:
 HCC = Hepatocellular CA, HA = Hemangioma, FNH = Focal Nodular Hyperplasia, LTP = Liver Tumor Program

CONTRIBUTORS: Hepatology, interventional Radiology, Radiology, Surgical Oncology, Medical Oncology, Radiation Oncology, Pathology

CONTACT: Dave Sanders, PA; Liver Tumor Program, Phone: 714-734-6295; Email: Dave.Sanders@stjoe.org
LIVER TUMOR PROGRAM CONFERENCE: First Tuesday of month, 5:30-7:00 pm
CONSULTATIONS: Online and telephone consultations available Monday through Friday, 9 am-4 pm
WEBSITE: www.sjo.org/liver